

## LETTER TO THE EDITOR

R. Kahveci · C. Sen · S. Akin · M. Özcan

**A case with Poland's syndrome and athelia**

Received: 4 May 1998 / Accepted: 22 June 1998

Poland's syndrome was first described by Alfred Poland in 1841 [1, 5]. The incidence has been estimated at between 1:30.000 and 1:80.000 of live births [4]. The syndrome is characterised by congenital aplasia of the sternocostal head of the pectoralis major muscle associated with ipsilateral hand deformities [6]. This rare entity is referred to as Poland's syndrome or Poland's syndactyly [3, 4, 7]. The former term seems to be more appropriate since multiple abnormalities of the upper extremity and the chest wall are usually associated with the syndactyly. Less frequently reported features of Poland's syndrome include the absence of digits, brachidactyly, hypoplasia of wrist and/or hand, hypoplasia of forearm, hypoplasia of arm, thoracic cage defects, herniation of lung, axillary web or band, absence of nipple and some genitourinary abnormalities [6, 7]. Congenital absence of the breast (amastia) and of the nipples (athelia) is an extremely rare anomaly which occurs more frequently in females [2, 4, 8, 9]. Around 50 cases have been described previously, the first was in 1802 by Louzier although there is some reference to this anomaly in the Bible.

A four-year-old boy presented with a small left hand with syndactyly since birth admitted to our clinic. On examination there was absence of the nipple and areola, the left pectoralis major muscle, hypoplasia of the left metacarpals and phalanges and syndactyly (Fig. 1, 2). Physical examination was otherwise normal. Chromosomal analysis of the patient was also normal. He was within normal limits in height weight and intelligence. The initial operation was a satisfactory syndactyly repair.

This boy with Poland's syndrome had unilateral absence of the breast and nipple, this is a very rare entity. This case emphasizes many relatively rare features of Poland's syndrome.

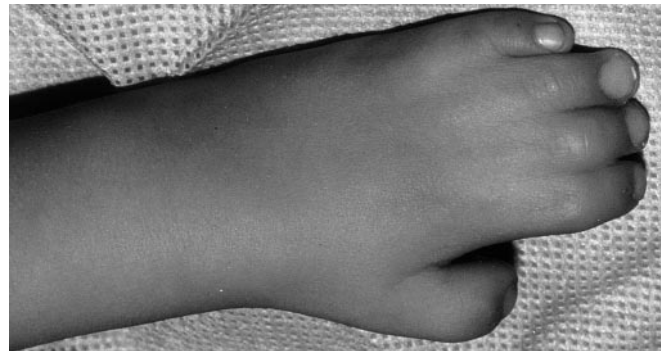

Fig. 1 Ipsilateral hand deformity

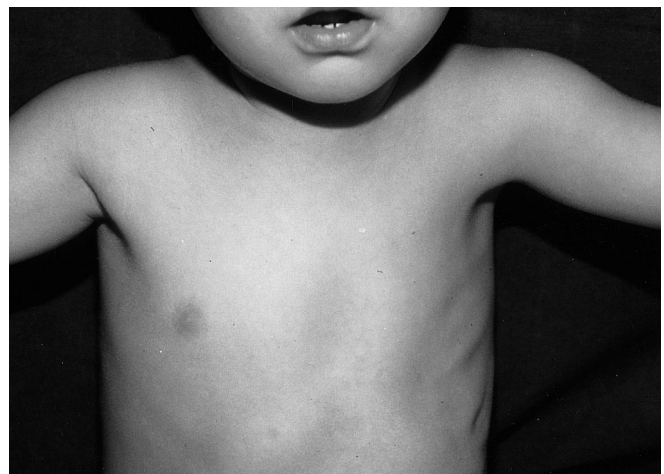


Fig. 2 Absence of the left nipple and areola

R. Kahveci (✉) · C. Sen · S. Akin · M. Özcan  
Uludağ Üniversitesi Tıp Fakültesi,  
Plastik Ve Rekonstrüktif Cerrahi A.D., Görükle,  
TR-16059 Bursa, Turkey  
Tel.: +90-224-4429-222; Fax: +90-224-4428-079

**References**

1. Poland A (1841) Deficiency of the pectoral muscles. *Guy's Hosp Rep* 6:191
2. Booth DH, Persaud TVN (1984) Congenital absence of the breast. *Anat Anz, Jena* 155:29
3. Bouvet JP, Leveque D, Bernetieres F, Gros JJ (1978) Vascular origin of Poland syndrome. *Eur J Pediatr* 128:17

4. Briner V, Thiel G (1988) Hereditäres Poland-Syndrom mit Megacalycose der rechten Niere. Schweiz Med Wochenschr 118:898
5. Clarkson P (1962) Poland's syndactyly. Guy's Hosp Rep 111:335
6. David TJ (1972) Nature and etiology of the Poland anomaly. N Engl J Med 287:487
7. Mace JW, Kaplan JM, Schanberger JE, Gotlin RW (1972) Poland's syndrome. Clin Pediatr 11:98
8. Ravitch MM (1977) Poland's syndrome – a study of an eponym. Plast Reconstr Surg 59:508
9. Versaci AD, Balkovich ME, Goldstein SA (1986) Breast reconstruction by tissue expansion for congenital and burn defects. Ann Plast Surg 16:20